

In general, rehydration behaviour under natural conditions is little known in small lizards, because it is arduous to approach them without interrupting their activity, and in this species, it has not been previous-

ly described. This opportunistic behaviour allows rapid rehydration in a dry rocky environment, completely devoid of water and subjected to elevated temperatures during the summer months.

REFERENCES

- Fornós, J.J. & Obrador, A. 2003. Geología de Menorca. 31–38. In: Roselló, V.M., Fornós, J.J. & Gómez, L.I. (eds.). *Introducción a la geografía física de Menorca: guía de campo de las XVII Jornadas de Geografía Física*. Societat d'Història Natural de les Balears i Universitat de les Illes Balears. Menorca.
- Mateo, J.A. 1997. *Lacerta perspicillata* Duméril & Bibron, 1839. Lagartija de Antejos, Lagartixa-moura, Sargantana mora. 367–368. In: Pleguezuelos, J.M. (ed.). *Distribución y Biogeografía de los Anfibios y Reptiles en España y Portugal*. Monografías de Herpetología, vol. 3. Asociación Herpetológica Española y Universidad de Granada. Granada.
- Mertens, R. 1929. *Lacerta (Scelarcis) perspicillata* Duméril et Bibron eine für Europa neue Eidechse. *Zoologischer Anzeiger*, 85:1–2.
- Perera, A. 2015. Lagartija de Marruecos - *Scelarcis perspicillata*. In: Salvador, A., Marco, A. (eds.). *Enciclopedia Virtual de los Vertebrados Españoles*. Museo Nacional de Ciencias Naturales, Madrid. <<http://www.vertebradosibericos.org/>> [Consulta: 19 julio 2022].

Limb malformations in a 1982 museum collection of *Pleurodeles waltl* larvae

Henrique Couto^{1,2,*} & Rui Rebelo¹

¹ CE3C – Centre for Ecology, Evolution and Environmental Changes. Faculty of Sciences. Campo Grande. 1749-016 Lisboa. Portugal.

² Sea Museum Rei D. Carlos. Rua Júlio Pereira de Mello. 2750-407 Cascais. Portugal. *C.e.: henriquenunocouto@gmail.com

Fecha de aceptación: 26 de septiembre de 2022.

Key words: amphibian deformities, historical record, morphology, museum study.

RESUMEN: Las malformaciones en extremidades están ampliamente documentadas en anfibios. En este artículo estudiamos los 32 individuos de *Pleurodeles waltl* de la colección del ‘Museu do Mar Rei D. Carlos’. Detectamos malformaciones en 26 de los 32 especímenes, de las cuales la mayoría se adscriben a braquidactilia (65%). Aunque no pudimos determinar las causas de estas malformaciones, estudios como este aumentan nuestro conocimiento de las mismas y su prevalencia.

Limb malformations in amphibians are well-known, especially among Caudata (Johnson *et al.*, 2003; Laurentino *et al.*, 2016). However, most of the reported cases are of single observations with malformation prevalences in a population, rarely exceeding 2% (Ouellet *et al.*, 1997; Vandenlangenberg *et al.*, 2003; Mester *et al.*, 2015; Martínez-Silvestre *et al.*, 2014; Laurentino *et al.*, 2016). The majority of reported cases show that the number and

proportion of limbs and digits (ectromelia – absence or unproportioned limbs; ectrodactyly – absence of digits; polymely – excess of limbs; and polydactyly – excess of digits) are the most common types of malformations (Ouellet, 2000; Laurentino *et al.*, 2016).

Several deformities have been registered in sharp-ribbed newts (*Pleurodeles waltl* Michaelles, 1830) such as: bifurcated limbs (Martins d’Alte, 1941), polymely, polydactyly, brachy-

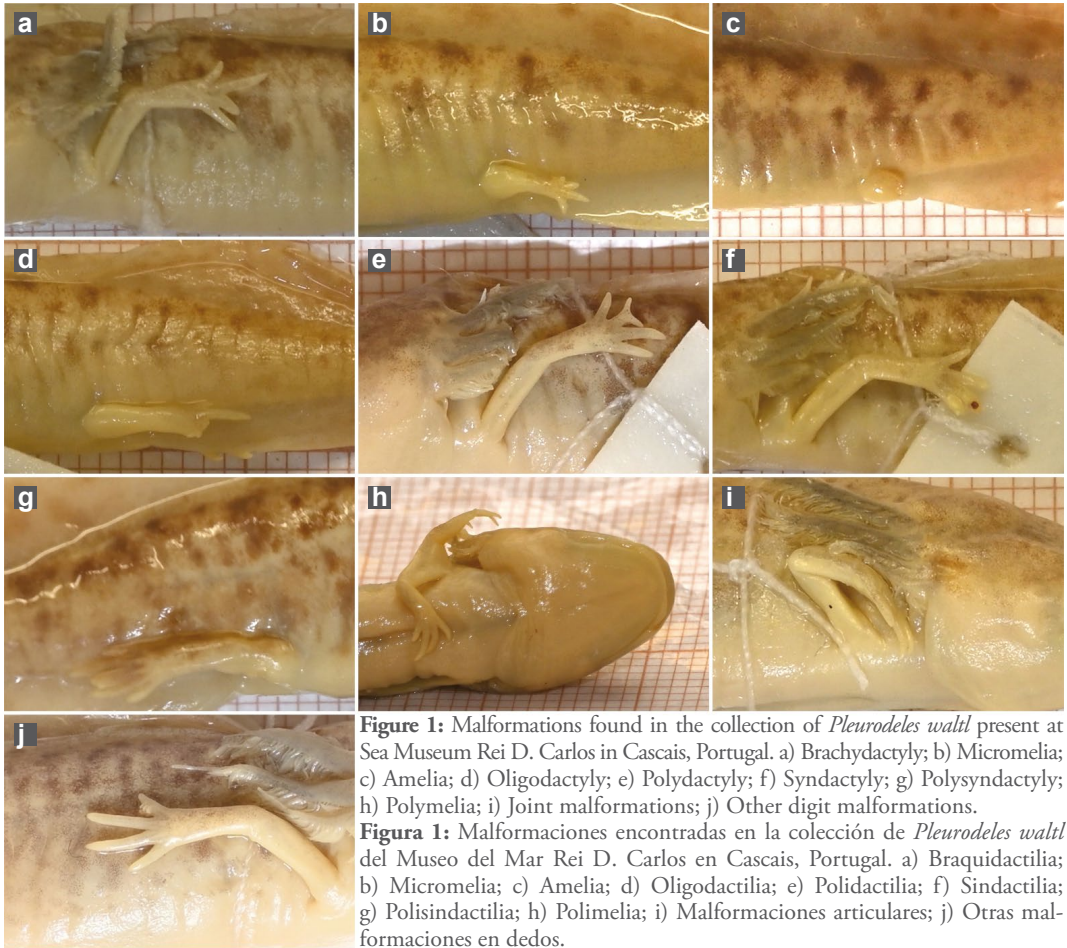


Figure 1: Malformations found in the collection of *Pleurodeles waltl* present at Sea Museum Rei D. Carlos in Cascais, Portugal. a) Braquidactilia; b) Micromelia; c) Amelia; d) Oligodactilia; e) Polidactilia; f) Sindactilia; g) Polisindactilia; h) Polimelia; i) Malformaciones articulares; j) Otras malformaciones en dedos.

Figura 1: Malformaciones encontradas en la colección de *Pleurodeles waltl* del Museo del Mar Rei D. Carlos en Cascais, Portugal. a) Braquidactilia; b) Micromelia; c) Amelia; d) Oligodactilia; e) Polidactilia; f) Sindactilia; g) Polisindactilia; h) Polimelia; i) Malformaciones articulares; j) Otras malformaciones en dedos.

dactyly (short digital bones) (Héron-Royer, 1884; Lyedig, 1879; Zamora-Camacho, 2016, 2020), limb synostosis (two or more bones fused together) (Sanchiz & Pérez, 1974), ectrodactyly, ectromelia (Lauthier, 1971, Zamora-Camacho, 2020), polyphalangy (presence of extra digital bones) (Torres & Hidalgo, 2016), syndactyly (fused digits) and ectrodactyly (Zamora-Camacho, 2020).

Here we report the case for the collection of the Sea Museum Rei D. Carlos (Cascais, Portugal) that holds 32 specimens of *Pleurodeles waltl* larvae conserved in 4% formaldehyde. We found that 26 out of these 32 specimens (over 80% of the collection) had limb mal-

formations (Table 1, Figure 1). All individuals were captured on March 30th, 1982 at Quinta do Marquês de Angeja in Alcabideche, Cascais (38°73'85"13N / 9°41'24"20W). Since 1982 the main water source has been diverted, and water quantity and quality are frequently compromised. It is doubtful that a relic population still persists.

The most common malformation was brachydactyly (Figure 1a) with over 65% of the affected individuals and over 50% of the collection having at least one malformation of this kind, followed by amelia (Figure 1c) (absence of limbs) and polydactyly (Figure 1e, g)

Table 1: Malformations found in the collection of *Pleurodeles waltl* present at Sea Museum Rei D. Carlos in Cascais per limb and in the total of individuals.

Tabla 1: Malformaciones encontradas por extremidad y en el total de individuos en la colección de *Pleurodeles waltl* del Museo del Mar Rei D. Carlos (Cascais).

Malformations	Limb				Individuals
	Forelimbs		Hindlimbs		
	Right	Left	Right	Left	
Brachydactyly	10	7	3	0	17
Micromelia	0	0	1	2	2
Amelia	1	1	1	1	4
Oligodactyly	0	0	0	1	1
Polydactyly	2	1	1	0	4
Syndactyly	0	1	0	0	1
Polysyndactyly	0	0	1	0	1
Polymelia	1	0	0	0	1
Joint malformations	1	1	0	0	2
Other digits malformations	3	1	0	0	4
Total	18	12	7	4	26

on over 15% of the individuals that had any malformation. Our findings support the idea that brachydactyly is one of the most common cases for skeletal malformations in urodeles (Diego-Rasilla *et al.*, 2007; Williams *et al.*, 2008). However, we also found syndactyly (Figure 1f, g) and polymelia (Figure 1h) that are among the most uncommon cases of malformations (Escoriza & García-Cardenete, 2005; Diego-Rasilla *et al.*, 2007; Williams *et al.*, 2008; Hinkley *et al.*, 2015).

Like most of the reported cases the reason(s) for the limb malformations could not be accessed (Johnson *et al.*, 1999; Blaustein & Johnson, 2003). Nonetheless the most commonly proposed reasons for limb deformities are related with the loss of limbs, extremely common during larval development due to predation and even cannibalism - and to the regeneration process, that does not always occur fully (Sessions & Ruth, 1990, Ballengée & Sessions, 2009; Bowerman *et al.*, 2010; Thompson *et al.*, 2014). However, there are other environmental and anthropogenic factors that are known to induce morphological malformations in amphibian populations such as parasites (Johnson *et al.*, 2003), pollution (Taylor *et al.*, 2005), UV radiation (Blaustein *et al.*, 1997), temperature (Dournon *et al.*, 1998) or the interac-

tion among factors (Ouellet, 2000; Johnson *et al.*, 2006; Laurentino *et al.*, 2016). A better knowledge on cases like this can be very important for amphibian conservation as the majority of reasons associated with malformations are also associated with mortality events (Blaustein *et al.*, 1994, 1997; Paull *et al.*, 2012; Hayden *et al.*, 2015).

Although we could not point out a reason for these malformations, registers like this increase the knowledge on amphibian malformations, and might contribute for future studies as a historical record for the presence of a population with a high prevalence of deformities. This is especially relevant when considering the rate amphibian populations are decreasing worldwide and in biodiversity hotspots in particular such as the case for the sharp-ribbed newt in the Iberian Peninsula.

ACKNOWLEDGEMENTS: We thank the team from Sea Museum Rei D. Carlos for the support and loaning the specimens for this study and a special thanks to C. Morais for the help on gathering data and information on the site. We thank F. Bravo from Quinta Marquês de Angeja for granting access to the site at the present. We are also grateful to G.M. Rosa for the support along the project, as well to S. Hughes and one reviewer for their comments on the manuscript.

REFERENCES

- Ballengée, B. & Sessions, S.K. 2009. Explanation for missing limbs in deformed amphibians. *Journal of Experimental Zoology B*, 312: 770–779.
- Blaustein, A.R., Hoffman, P.D., Hokit, D.G., Kiesecker, J.M., Walls, S.C. & Hays, J.B. 1994. UV repair and resistance solar UV-B in amphibian eggs: A link to population declines? *Proceedings of the National Academy of Sciences of the United States of America*, 91(5): 1791–1795.
- Blaustein, A.R. & Johnson, P.T.J. 2003. The complexity of deformed amphibians. *Frontiers in Ecology and the Environment*, 1: 87–94.
- Blaustein, A.R., Kiesecker, J.M., Chivers, D.P. & Anthony, R.G. 1997. Ambient UV-B radiation causes deformities in amphibian embryos. *Proceedings of the National Academy of Sciences of the United States of America*, 94(13): 735–737.
- Bowerman, J., Johnson, P.T.J. & Bowerman, T. 2010. Sublethal predators and their injured prey: linking aquatic predators and severe limb abnormalities in amphibians. *Ecology*, 91: 242–251.
- Diego-Rasilla, F.J., Luengo, R.M. & Rodríguez-García, L. 2007. *Triturus marmoratus* (Marbled Newt). Limb abnormalities. *Herpetological Review*, 38: 68.
- Dournon, C., Bautz, A., Membre, H., Lauthier, M. & Colletot, A. 1998. Expression of hindlimb abnormalities under rearing temperature effects during the larval development of the salamander *Pleurodeles waltl* (urodele amphibian). *Development, Growth & Differentiation*, 40: 555–565.
- Escoriza, E. & García-Cardenete, L. 2005. Polimelia en *Alytes dickhilleni* y *Salamandra salamandra longirostris*. Dos casos de ejemplares con seis extremidades. *Boletín de la Asociación Herpetológica Española*, 16: 39–41.
- Hayden, M.T., Reeves, M.K., Holyoak, M., Perdue, M., King, A.L. & Tobin, S.C. 2015. Thrive as easy to catch! Copper and temperature modulate predator-prey interactions in larval dragonflies and anurans. *Ecosphere*, 6(4:56): 1–17.
- Héron-Royer, L.F. 1884. Cas tératologiques observés chez quelques rétards de batraciens anoures et de la possibilité de prolonger méthodiquement l'état larvaire chez les batraciens. *Bulletin de la Société Zoologique de France*, 9: 162–168.
- Hinckley, A., Goedbloed, D. & Küpfer, E. 2015. First record of limb abnormalities in the Near Eastern fire salamander (*Salamandra atra*). *The Herpetological Bulletin*, 133: 36–37.
- Johnson, P.T.J., Lunde, K.B., Ritchie, E.G. & Launer, A.E. 1999. The effect of trematode infection on amphibian limb development and survivorships. *Science*, 284: 802–804.
- Johnson, P.T., Lunde, K.B., Zelmer, D.A. & Werner, J.K. 2003. Limb Deformities as an emerging parasitic disease in amphibians: Evidence from museum specimens and resurvey data. *Conservation Biology*, 17(6): 1724–1737.
- Johnson, P.T., Preu, E.R., Sutherland, D.R., Romansic, J.M., Han, B. & Blaustein, A.R. 2006. Adding infection to injury: Synergistic effects of predation and parasitism on amphibian malformations. *Ecology*, 87(9): 2227–2235.
- Laurentino, T.G., Pais, M.P. & Rosa, G.M. 2016. From a local observation to a European-wide phenomenon: Amphibian deformities at Serra da Estrela Natural Park, Portugal. *Basic and Applied Herpetology*, 30: 7–23.
- Lauthier, M. 1971. Etude descriptive d'anomalies spontanées des membres postérieurs chez *Pleurodeles waltl* Michah. *Annales d'embryologie et de morphogénèse*, 4: 65–78.
- Leydig, F. 1879. Die rippenstacheln des *Pleurodeles waltl*. *Archiv für Naturgeschichte, Jahrgang*, 45: 211–234.
- Martínez-Silvestre, A., Amat, F. & Carranza, S. 2014. Natural incidence of body abnormalities in the Montseny newt, *Calotriton arnoldi* Carranza and Amat, 2005. *Herpetology Notes*, 7: 277–279.
- Martins d'Alte, J.A. 1941. Notas tertológicas - VII - Bifidez do membro anterior num *Pleurodeles*. *Anais da Faculdade de Ciências do Porto*, 26(4): 245–249.
- Mester, B., Lengyel, S. & Puky, M. 2015. Low frequency of amphibian morphological anomalies in a large protected wetland and grassland complex in Hungary. *Herpetological Conservation and Biology*, 10: 679–687.
- Ouellet, M. 2000. Amphibian deformities: current state of knowledge. 617–661 In: Sparling, D.W., Linder, G. & Bishop, C.A. (eds.). *Ecotoxicology of Amphibians and Reptiles*. SETAC Press. Pensacola. Florida. USA.
- Ouellet, M., Bonin, J., Rodrigue, J., DesGranges, J.L. & Lair, S. 1997. Hindlimb deformities (ectromelia, ectrodactyly) in free-living anurans from agricultural habitats. *Journal of Wildlife Diseases*, 33: 95–104.
- Paull, S.H., LaFonte, B.E. & Johnson, P.T.J. 2012. Temperature-driven shifts in a host-parasite interaction drive nonlinear changes in disease risk. *Global Change Biology*, 18(12): 3558–3567.
- Sanchiz, F.B. & Pérez, P.J. 1974. Frecuencia de anomalías óseas en la población de *Discoglossus pictus* (Anura, Discoglossidae) de Campos (Asturias). *Boletín de la Estación Central de Ecología*, 3(6): 69–77.
- Sessions, S.K. & Ruth, S.B. 1990. Explanation for naturally occurring supernumerary limbs in amphibians. *Journal of Experimental Zoology*, 254: 38–47.
- Taylor, B., Skelly, D., Demarchis, L.K., Slade, M.D., Galusha, D. & Rabinowitz, P.M. 2005. Proximity to pollution sources and risk of amphibian limb malformation. *Environmental Health Perspectives*, 113(11): 1497–1501.
- Thompson, S., Muzinic, L., Muzinic, C., Niemiller, M.L. & Voss, S.R. 2014. Probability of regenerating a normal limb after bite injury in the Mexican axolotl (*Ambystoma mexicanum*). *Regeneration*, 1: 27–32.
- Torres, J.M. & Hidalgo, E. 2016. Polyphalangy incidence in an isolated population of *Pleurodeles waltl* found in a rural well in the Southwest of Spain. *Boletín de la Asociación Herpetológica Española*, 27(2): 40–43.
- Vandenlangenberg, S., Canfeld, J. & Magner, J. 2003. A regional survey of malformed frogs in Minnesota (USA). *Environmental Monitoring and Assessment*, 82: 45–61.

Williams, R.N., Bos, D.H., Gopurenko, D. & DeWoody, J.A. 2008. Amphibian malformations and inbreeding. *Biology Letters*, 4: 549–552.

Zamora-Camacho, F.J. 2016. Anomalías múltiples en diversas extremidades en *Pleurodeles waltl*. *Boletín de la*

Asociación Herpetológica Española, 27(2): 22–24.

Zamora-Camacho, F.J. 2020. Morphological abnormalities in a population of *Pleurodeles waltl* (Caudata: Salamandridae) from southwestern Spain. *Phyllomedusa*, 19(1): 131–135.

Lesiones cutáneas en *Natrix maura* causadas por *Pachygrapsus marmoratus* (Decapoda, Brachyura)

Juan J. Pino-Pérez¹ & Rubén Pino-Pérez²

¹ Cl. A Fraga, 7. Corzans. 36457 Salvatierra de Miño. Pontevedra. España. C.e.: pino@uvigo.es

² Cl. Sierra Poniente, 18. 36940 Cangas. Pontevedra. España

Fecha de aceptación: 7 de noviembre de 2022.

Key words: Galicia, marbled rock crab, Spain, viperine snake, wounds.

Natrix maura es una especie de colúbrido frecuente en la costa de Pontevedra, incluyendo el Parque Nacional de las Islas Atlánticas de Galicia (Galán & Fernández-Arias, 1993; Pino *et al.*, 1998). Estas poblaciones costeras, bien adaptadas al ambiente marino (Galán, 2003), suelen alimentarse en la zona intermareal rocosa, en las pozas de marea

atacando diferentes especies de blénidos y góbidos. Según nuestras observaciones, en las áreas costeras del municipio de Cangas (Pontevedra), los individuos suelen ser menores de 60 cm de longitud total y se alimentan principalmente del blénido *Lipophrys pholis* (Linnaeus, 1758), del góbido *Gobius paganellus* Linnaeus, 1758 y del



Figura 1: *Natrix maura* atacadas por: a) un macho y b) una hembra de *Pachygrapsus marmoratus* a 2 m de profundidad en una grieta intermareal, el 29 de julio de 2004, en Cangas, Pontevedra (29T 516485; 4677602).